Patellar Osteochondral Fragment Fixation Using ActivaPin™ - 11 Year-old Child

Juha-Jaakko Sinikumpu
M.D., Ph.D.
Pediatric Orthopedic Surgeon

For medical professional use, not public

bioretec

Bioretec develops and produces globally innovative bioabsorbable products and surgical solutions for better patient outcome, user friendliness and cost-efficiency in clinical care.

Bioretec Ltd. • Hermiankatu 22 • FI-33720 Tampere • Finland
Tel. +358 20 778 9500 • Trade Reg. No. 738.932 • VAT No. FI14741969
sales@bioretec.com • **www.bioretec.com**

bioretec

Table of Contents

Summary Table 3
1 Case Description 4
2 Surgical Procedure 5
3 Results 7
3.1 3 Weeks After Operation 7
3.2 6 Weeks After Operation 7
3.3 13 Months After Operation 9
4 Discussion and Conclusion 9
5 Contact Information Concerning the Case 11
6 References 11

bioretec

Summary Table

Demographics

Patient number:		Patient Initials:	J.P.	Note:
Smoking:	No	Sex:	Female	
Use of alcohol:	No	Age:	13 Years	
Systemic disease:	No	Height:	159 cm	
Cont. Medication:	No	Weight:	52 kg	

Case description

Injury date:	07/11/14	Diagnosis number:	S82.0	Note:
Diagnosis:	Fractura osteochondralis patellae l.dx.			
Cause of injury:	Fall. Distorsion of the knee.			

Operation

Operator:	J-J Sinikumpu	Operation date:	13/11/14	Note:
Operation description:	Fixatio corpus osteochondralis patellae (ActivaPin No III)			
Operation time:	h min	Immobilisation method:	Brace	
Hospital stay:	4 Days	No weight bearing:	2 Weeks	
Sick leave:	0 Days	Partial weight bearing:	2. - 5. Weeks	
Bloodless field during operation:	Yes			
Prophylactic antibiotics:	Yes	If Yes, Name of Antibiotic:	kefuroxin	
Implant 1:	ActivaPin	Size: 2.0 x 30	LOT: S	
Comments on implantation:				
Implant 2:	ActivaPin	Size: 1.5 x 30	LOT: S	
Comments on implantation:				
Implant 3:	ActivaPin	Size: 1.5 x 30	LOT: S	
Comments on implantation:				
Implant 4:		Size: x	LOT: S	
Comments on implantation:				

Follow up

	Post Operative	Follow up 1	Follow up 2	Follow up 3	Follow up 4
Date:	14/11/14	01/12/14	22/12/14	21/01/16	
Time after operation (Weeks):	-	3	6	61	-
Obj. result:	Excellent	Excellent	Excellent	Excellent	
Subj. result:	Excellent	Excellent	Excellent	Excellent	
Radiological position:	Not acceptable	Not acceptable	Excellent	Excellent	
Radiolog. parameter (mm, deg):					
Bone union:	-	-			
Swelling:	Slight swelling	No swelling	Slight swelling	No swelling	
Redness:	Slight redness	No redness	No redness	No redness	
Tissue reaction:	No tissue reaction	No tissue reaction	No tissue reaction	No tissue reaction	
Pain:	Severe (continuous med.)	No pain	Slight pain (no medication)	No pain	
Range of motion:	Not applicable	Not applicable	Deficiency >30 deg	Normal	
Physical activities:	Very limited activity	Very limited activity	Modified activity	Like before	
Infection:	No infection	No infection	No infection	No infection	
Reoperation:	No	No	No	No	

1 Case Description

The patient was an 11-year old female who did not have any chronic disease. She was 149.5 cm in height and weighed 52 kg. The patient fell while bicycling and injured her right knee. It was a rotational motion injury, resulting in the development of a large edema and tenderness. Other key clinical finding was a decreased range of motion of the knee: Flexion range was restricted to 45-40 degrees. Extension range was normal. Skin was intact. Ligamentous stability or instability could not be assessed upon admission because of acute pain.

In the primarily radiographs a loose bone fragment was seen in the knee joint (Figure 1). It was located in the eminentia area but the origin of the fragment was not clear. A computer tomography (CT) imaging was performed. The CT showed that the fragment was originating from a stress-bearing area, the distal apex of the patellae. It was about 10x10 mm in size and it comprised both joint cartilage surface and a thin layer of underlying bone tissue (Figure 2). No other acute musculoskeletal findings were seen in the CT.

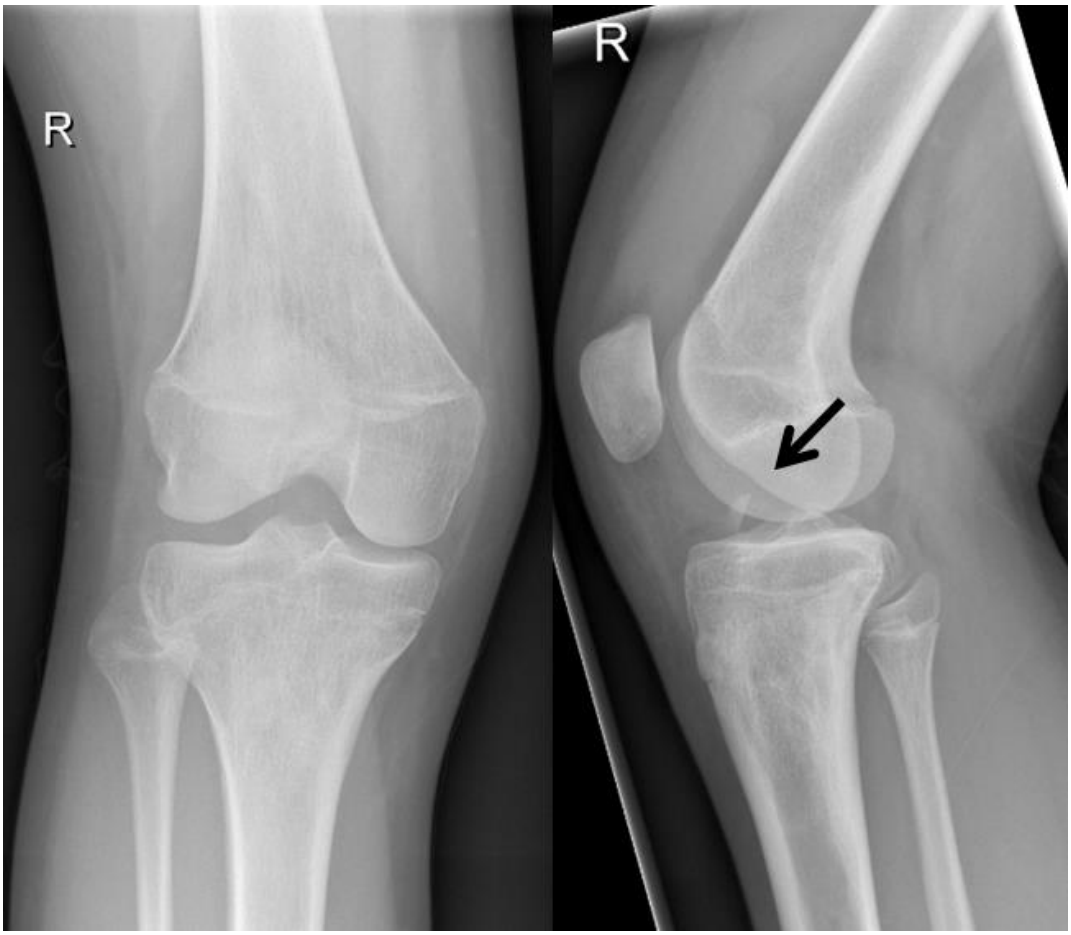

Figure 1 Primary radiographs showed a loose bone fragment in the knee joint

Figure 2 CT showed that the fragment was originating from a stress-bearing area, the distal apex of the patellae.

2 Surgical Procedure

Five days later a surgical operation was performed at the tertiary pediatric trauma unit by a senior consultant. Clinical investigation was repeated preoperatively under general anesthesia and no instability was found. Lateral entry was used in the arthroscopy. Hemarthron was treated by rinsing the joint generously with sterile NaCl 0.9% solution. A large osteochondral defect was found in the

patellae, matching with the corresponding finding in the CT imaging, except that the size was greater because of roentgen-negative cartilage tissue. The fragment was found in the tibiofemoral joint space.

Arthrotomy was necessary due to the small dimensions of the child patient, instead of arthroscopy guided fixation. The knee was drained empty and a vertical parapatellar approach was performed. Soft tissues were dissected to approach the patella. The patella was then everted 90 degrees laterally using AO-forceps, in order to get direct access to the injury lesion. The surface of the defect area was rasped. The loose part was adjusted into the defect. It was discreetly compressed against the patellar bone, followed by a contemporary fixation by two 1.4 mm Kirshner wires and one 2.0 mm Kirschner wire. Thereafter, the wires were replaced by two **ActivaPin™ 1.5 mm** and one **ActivaPin™ 2.0 mm**. The pins were inserted using an ActivaPin™ Applicator. No notch or unevenness was remaining at the joint surface (Figure 3). The stability was good after fixing the fracture with three pins.

Figure 3 The loose part was adjusted into the defect and fixed using three ActivaPin™s

After having the fracture fixed, the patella was repositioned to its anatomic location by inverting it. The surgical wound was closed with biodegradable sutures in a few layers. The tendon-like part of the vastus medialis muscle that

was partially incised initially was tightly sutured. The joint capsule and medial retinaculum were also reconstructed by weaved resorbable thread. Subcutaneous tissue was brought closer by single knots. The skin was finally closed with metal staples.

An individual shell plaster was postoperatively applied using flexible synthetic material. It was strengthened by stiff glass fiber splints at both sides of the extremity. No weight bearing was allowed during the next two weeks to protect the patellae from compression against the femoral trochlear sulcus. Forearm crutches were used during this time.

3 Results

3.1 3 Weeks After Operation

Three weeks after the operation, the patient visited an operating surgeon at an out-hospital clinic. The immobilization was released and the skin staples were removed. The wound was healing well without complication. No gleam, flush or edema was seen.

A hinge joint orthosis was ordered to avoid further patellar pressure and traction at the surgical wound. Flexion range of motion was restricted by just 20 degrees. Isometric physical exercises were instructed by a physiotherapist familiar with pediatric trauma. Partial weight bearing was allowed (approx. 25 kg).

3.2 6 Weeks After Operation

6 weeks after the operation the surgical wound was good. There was a slight decrease of flexion range while the joint orthosis treatment was relaxed. Nevertheless, the restriction of motion was soft-end-point and benign of nature. There was no tenderness in the knee.

In the follow-up radiographs the loose bone part was ossifying. The patellar joint surface looked smooth (Figure 4). Physiologic osteopenia was seen overall in the knee radiographs, resulting from immobilization of the lower extremity in several weeks. A CT was performed to evaluate the final outcomes about two months after operation. Good bone healing was seen (Figure 5). The femoral-patellar joint seemed intact.

Figure 4 In radiographs six weeks after operation, the loose bone part was ossifying and the patellar joint surface looked smooth.

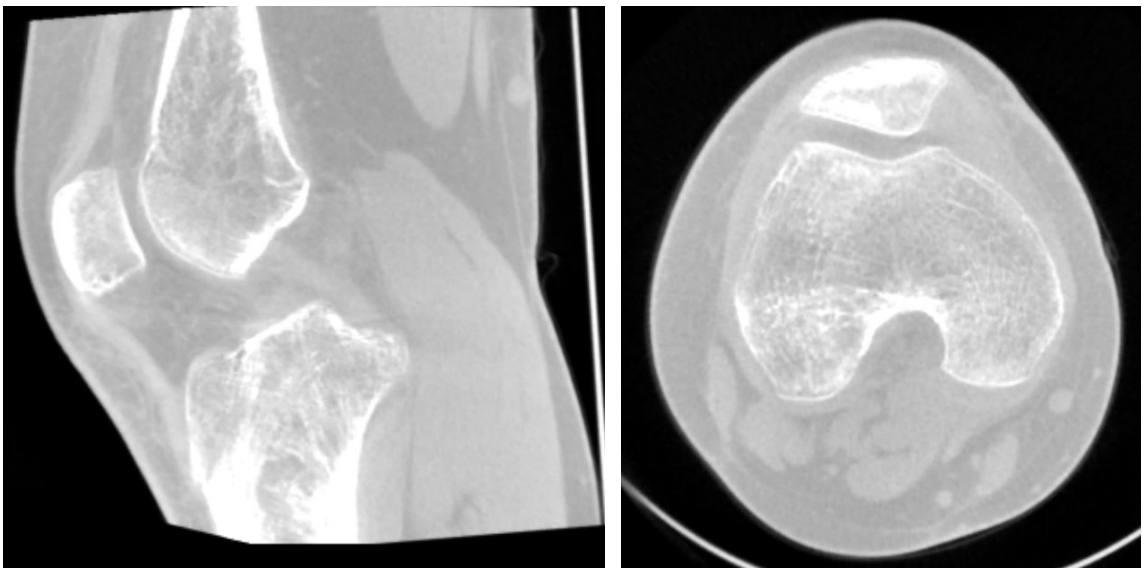

Figure 5 CT was performed to evaluate the final outcomes about two months after operation. Good bone healing was seen. The femoral-patellar joint seemed intact.

3.3 13 Months After Operation

The long-term result was determined 13 months after the operation. The knee was symptomless. It was stable and the range of motion (ROM) was normal. The joint surface was smooth and intact in CT imaging (Figure 6). The follow-up was finished.

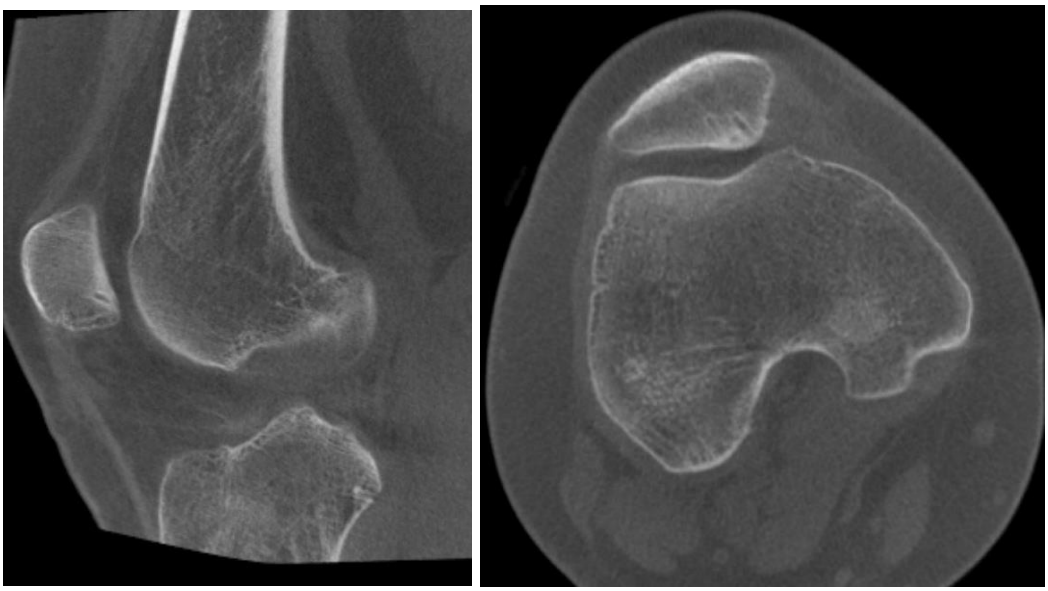

Figure 6 CT images, taken 13 months after operation, showed smooth and intact joint surface.

4 Discussion and Conclusion

Injury based osteochondral fracture is a common reason for cartilage loss of children's knees. The damage of patellar bone is usually related with patellar displacement or luxation. The prevalence of osteochondral fractures in children is unknown (Chotel et al. 2011). However, in case of knee hemarthrosis, the incidence of patellar osteochondral fractures is as high as 5% (Vähäsarja et al. 1993). The fracture may not be recognized in normal radiographs due to the high amount of roentgen-negative chondral tissue. Magnetic resonance imaging is the preferred method to evaluate the damage (Vellet et al. 1991). In regards to our case, a small bone component of the loose fragment was visible in the normal radiographs. Its origin was unclear meaning that a computer tomography was performed.

It is important to salvage the cartilage joint surface of a growing child to prevent them from later symptomatic and early-onset osteoarthrosis (Kramer et al. 2012). Extirpation of the loose fragment is not a desired operation, because it results in

fibrocartilage tissue formation (Scopp 2004). Amotion of the loose fragment can be a suitable option for small fractures not involved in the central part of the joint or stress-bearing area in children. In general, cartilage damage is a decisive factor for long-term prognosis in patellar injury (Schmal et al. 2010).

Surgical repositioning and fixation of the fragment is the preferred method of treatment in patellar fragments, if possible. Many techniques for stabilization have been used, while screw and pins are the most common of them. Simple casting of the lower extremity is not a stable enough method of treatment in the case of a loose bone part in the knee joint (Chotel et al. 2011). Timing may be a determinant regarding the recovery of the fragment, meaning that the operation needs to be performed during the first two weeks after injury (Toupin et al. 1997).

There are severe problems with metal implants. They may cause late morbidity in the knee joint surface and they may require a secondary operation for removal. The main advantage of a resorbable implant is that a second operation to remove the implants is not needed (Chotel et al. 2011). Biodegradable pin fixation in the knee is safe and useful (Matsusue et al. 1996). Several types of resorbable implants, such as screws, pins and nails have been used (Fuchs et al. 2003). Despite their better compression, the problem with screws is the prominence of the screw head that may result to uneven surface of the joint, compared with pins that will be tapped inside the cartilage (Hirsch et al. 1998, Chotel et al. 2011). In our case, satisfactory good compression was achieved by polylactide-co-glycolide pins. A tight “drill” hole was made using a Kirschner wire as a bore bit, instead of a proper drilling. The stability of fixation was manually tested during the operation. Furthermore, the material of the implant is going to swell 1% when it is in contact with the human tissue, further increasing the rigidity of the fixation.

The patient demonstrated good recovery in the follow-up. The challenges were related to postoperative immobilization rather than actual operation. Radiographic ossifying of the loose fragment was complete. The CT imaging demonstrated intact joint surface.

In conclusion, the polylactide-co-glycolide pins resulted in excellent outcomes when they were used in fixation of patellar osteochondral fragment in a growing child. Ossifying was good in 6 weeks postoperatively, without complications. A satisfactory outcome was still found in the long-term follow-up.

5 Contact Information Concerning the Case

Juha-Jaakko Sinikumpu, M.D., Ph.D.
Pediatric Orthopedic Surgeon
Department of Pediatric Surgery and Orthopedics, Oulu University Hospital, Finland

6 References

[1] Chotel, F., et al. "Knee osteochondral fractures in skeletally immature patients: French multicenter study." Orthopaedics & Traumatology: Surgery & Research 97.8 (2011)

[2] Vähäsarja, Vesa, Pentti Kinnuen, and Willy Serlo. "Arthroscopy of the acute traumatic knee in children: prospective study of 138 cases." Acta Orthopaedica 64.5 (1993): 580-582.

[3] Kramer, Dennis E., and J. Lee Pace. "Acute traumatic and sports-related osteochondral injury of the pediatric knee." Orthopedic Clinics of North America 43.2 (2012): 227-236.

[4] Scopp, Jason M., and Bert R. Mandelbaum. "Cartilage Restoration." The journal of knee surgery 17.4 (2004).

[5] Schmal, Hagen, et al. "Fractures of the patella in children and adolescents." Acta Orthopaedica Belgica 76.5 (2010): 644.

[6] Toupin, J. M., and J. Lechevallier. "[Osteochondral fractures of the external femoral condyle after traumatic patellar dislocation during physical exercise in children]." Revue de chirurgie orthopedique et reparatrice de l'appareil moteur 83.6 (1996): 540-550.

[7] Matsusue, Yoshitaka, et al. "Biodegradable pin fixation of osteochondral fragments of the knee." Clinical orthopaedics and related research 322 (1996): 166-173.

[8] Fuchs, M., et al. "[Refixation of osteochondral fragments using absorbable implants. First results of a retrospective study]." Der Chirurg; Zeitschrift fur alle Gebiete der operativen Medizen 74.6 (2003): 554-561.

[9] Hirsch, Georg, and Anders Boman. "Osteochondral Fractures of the Knee in Children and Adolescents Treatment with Open Reduction and Osteosynthesis Using Biodegradable Pins." Techniques in Orthopaedics 13.2 (1998): 139-142.