Bioretec Research and Development

Fixation of physeal fractures with bioabsorbable implants

Table of Contents

bioretec

Bioretec develops and produces globally innovative bioabsorbable products and surgical solutions for better patient outcome, user friendliness and cost-efficiency in clinical care.

Bioretec Ltd. • Hermiankatu 22 • FI-33720 Tampere • Finland
Tel. +358 20 778 9500 • Trade Reg. No. 738.932 • VAT No. FI14741969
sales@bioretec.com • **www.bioretec.com**

1. Introduction

Physes are cartilageous structure that are very prone to fracture. Different physes respond differently to injury, and each must be considered separately, main factors are the child's age, the growth potential of the affected area, the location, and the type of injury. The main long-term complication of physeal injuries is partial/full growth arrest which may cause several problems to the limb growth, such as angular deformities or limb discrepancy.

In this report, the anatomy of the physes is explained and different fixation methods are considered based on spesific anatomic location. Especially, the use of bioabsorbable devices is reviewed.

2. Anatomy of the growth plate

The growth plate, also known as the epiphyseal plate or physis, is the area of growing tissue near the ends of the long bones in children and adolescents. Each long bone has at least two growth plates, one at each end that determine the future length and shape of the mature bone. Growth plate is an unique cartilaginous structure that varies in thickness depending on age, location [1] and its growth potential (the rate of production of new chondrocytes at the top of the proliferative zone). [2] After the growth is complete the growth plates are resorbed and replaced by primary spongiosa. Finally, it fuses the epiphysis to the metaphysis. Timing of growth plate closure of different bones are presented in Figure 1.

Growth plates tolerate torsion, shear, and bending worse than solid bone, since they are the weakest points of the growing skeleton, even weaker than the nearby ligaments and tendons. Consequently, growth plates are remarkable prone to injury. [4]

Growth plates are traditionally divided into four zones: reserve (resting/germinal), proliferative, hypertrophic, and provisioinal calcification (or enchondral ossification) zones. [1] These are presented in Figure 2.

Bone	Appearance of secondary ossification centres – girls	Timing of physeal fusion – girls	Appearance of secondary ossification centres – boys	Timing of physeal fusion – boys
Femur				
Femoral head	4 months	16–17	4 months	17–18
Greater trochanter	3 years	16–17	3 years	16–17
Lesser trochanter	11 years	16–17	12 years	16–17
Distal epiphysis	36 weeks (foetal)	17	36 weeks (foetal)	18–19
Tibia				
Proximal epiphysis	40 weeks (foetal)	16–17	40 weeks (foetal)	18–19
Tibial tuberosity	7–15 years	19	7–15 years	19
Distal epiphysis	6 months	17–18 *Medial malleolus fuses at 16	6 months	17–18 *Medial malleolus fuses at 18
Fibula				
Proximal epiphysis	3 years	16–18	4 years	18–20
Distal epiphysis	9 months	17–18	1 year	17–18
Humerus				
Humeral head	Birth-3 months	*Head and tuberosities fuse 4–6 years	Birth-3 months	*Head and tuberosities fuse 4–6 years
Greater tuberosity	3 months–1.5 years	*Proximally fuse to shaft 18–20 years	6 months–2 years	*Proximally fuse to shaft 19–21 years
Lesser tuberosity	3–5 years	*Capitellum, lateral epicondyle, and trochlea fuse to shaft at 14 years	3–5 years	*Capitellum, lateral epicondyle, and trochlea fuse to shaft at 17 years
Capitellum	4 months	*Medial epicondyle fuses at 15 years	5 months	*Medial epicondyle fuses at 18 years
Medial epicondyle	5 years		7 years	
Trochlea	8 years		9 years	
Lateral epicondyle	11 years		12 years	
Radius				
Proximal epiphysis	4 years	14–15	5 years	15–17
Distal epiphysis	1 year	17	1 year	19
Ulna				
Olecranon	8 years	14–15	10 years	14–17
Distal epiphysis	5 years	17 *Styloid closes at 18–20	6 years	19 *Styloid closes at 18–20

Figure 1: Timing of initial ossification and physeal fusion of ossification centers of the long bones. **[3]**

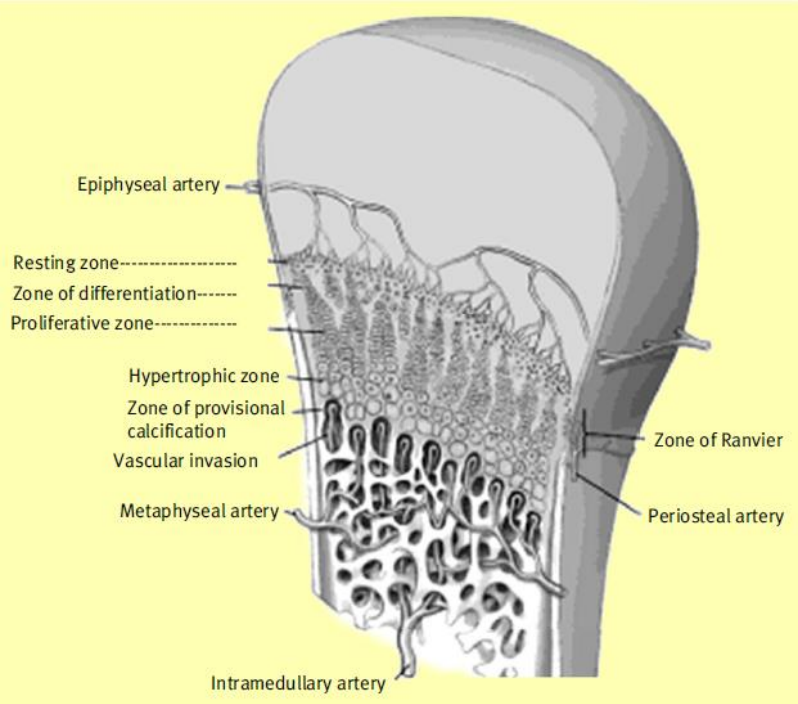

Figure 2: Schematic figure of the zones and vascular supply. **[5]**

In the resting zone, germinal cells of stem cells can be found. They exist in a low oxygen tension area and respond to circulating hormones. During the cell proliferation, cells appear as thin disks and palisades. There is a mechanically strong thick layer of matrix that protects small cells resting and proliferative zones. In the extracellular matrix (an area of high oxygen tension), longitudinal orientation of the collagen fibers occurs. In the hypertrophic zone, there isn't much space to the matrix and its strengthening effect, because of hypertrophy of the chondrocytes. Consequently, it is the weakest layer of the physis under tension, shear, and bending stress, and it is the most common area for fractures. In the zone of provisional calcification, metaphyseal vascular invasion allows mineralization of the matrix to occur, and programmed cell death of the chondrocytes is initiated. This occurs due to osteoblasts and osteoclasts, which comes to the zone by vascular invasion and initiate the formation of the primary spongiosa and its subsequent remodeling to more mature secondary spongiosa that no longer contains remnants of the cartilaginous precursor. [6]

The physis is connected to the epiphysis and metaphysis peripherally via the zone of Ranvier and the perichondral ring of LaCroix. The zone of Ranvier is a circumferential notch containing cells s osteoblasts, chondrocytes, and fibroblasts), fibers, and a bony lamina located at the periphery of the physis. Whereas, the perichondral ring of LaCroix is a strong fibrous structure that secures the epiphysis to the metaphysis.

The vascular network can be classified into two types. [7] Type A epiphyses are covered almost entirely by articular cartilage and in there the blood supply enters from the metaphyseal side of the physis and is therefore prone to injury during epiphyseal separation. Type A epiphyses can be found only in the proximal femur and proximal radius. Type B epiphyses are only partially covered by articular cartilage, and in there the blood supply enters from the epiphyseal side of the physis and is therefore protected from injury during epiphyseal separation. [6]

The blood supply to the growing bone includes a rich metaphyseal circulation with fine capillary loops ending at the physis. [1] The blood supply is originated from three different sources: epiphyseal arteries, metaphyseal arteries and perichondral circulation. [3] If this circulation, especially the epiphyseal one, is destructed (e.g. with a screw), growth disorders are likely. [8] Basener et al. reported 30–65% of growth plate fractures resulted in some level of growth disturbance, depending on the type and location of the fracture. [9] It is repoted that growth arrest occurs in 5-10 % of all cases [3]. In Figure 3 can be seen the calculated probabilities to physeal bar formation in different cases.

If the physeal bar has already formed to the growth plate, to prevent impaired growth, current treatment options involve removal of the bony bar and replacement with fat, muscle, cartilage, polymeric silicone, bone wax, or bone cement as interpositional materials. [11, 12, 13] However, in some patients, this has only a temporary positive effect on the growth, until the bony bridge grows back. [14]

Variable	Bar	No bar	Total	Percentage with bar (95% CI*)	p-value
Total incidence	12	43	55	*21.8* (11.8 to 35.0)	
Age					
Juvenile	8	23	31	*25.8* (11.9 to 44.6)	0.5
Adolescent	4	20	24	*16.7* (4.7 to 37.4)	
Mechanism					
High-energy	11	25	36	*30.6* (16.3 to 48.1)	0.04
Low-energy	1	18	19	*5.3* (0.1 to 26.0)	
Salter-Harris type					
I	0	4	4	*0.0* (0.0 to 60.2)	Trend < 0.0001
II	8	38	46	*17.4* (7.8 to 31.4)	
III	1	1	2	*50.0* (1.3 to 98.7)	
IV	3	0	3	*100.0* (29.2 to 100.0)	
Displacement					
Medial	5	16	21	*23.8* (8.2 to 47.2)	0.08
Lateral	1	8	9	*11.1* (0.3 to 48.2)	
Anterior	1	18	19	*5.3* (0.1 to 26.0)	
Posterior	1	0	1	*100.0* (2.5 to 100.0)	
Intra-articular	4	1	5	*80.0* (28.4 to 99.4)	N/A†
Treatment					
Plaster	3	8	11	*27.3* (6.0 to 61.0)	0.2
Pinning	7	33	40	*17.5* (7.3 to 32.8)	
Screws	2	2	4	*50.0* (6.8 to 93.2)	

* CI, confidence interval. All 95% CIs were two-sided exact CIs, except where proportions were 0.0 or 100.0, where one-sided exact CIs were calculated

† N/A, not available

Figure 3: The propability of the physeal bar formation in different relations. **[10]**

3. Growth-plate injuries

3.1. Frequency

Physeal fractures cover 15-20 % of all major long-bone fractures [15] and even 34 % of pediatric hand fractures [15]. Physeal fractures are twice as common in boys as in girls. This could be explained by the fact that the physes are open for a longer period of time in boys. The most common physeal fractures involve the phalanges of the fingers, distal radius, and distal tibia. Anyway, the distal physes tend to be injured more frequently than

proximal physes. In addition upper limbs tend to be more commonly injured than lower limbs. [6] In addition generally boys participate in more risk-taking behavior and athletics.

Most of the physeal fractures are results of compression, torsion or bending moments. Compression fractures are found usually at metaphyseal diaphyseal junction and are referred to as buckle fractures or torus fractures. Torsional injuries result in two distinct patterns of fracture depending on the maturity of the physis. In very young child with a thick periosteum, the diaphyseal bone fails before the physis, resulting in a long spiral fracture. In the older child, similar torsional injury results in a physeal fracture. Bending moments in young children cause “greenstick fractures” in which the bone is incompletely fractured, resulting in a plastic deformity on the convace side of the fracture. [1]

3.2. Classification

Pediatric physeal fractures have traditionally described by the Slater-Harris classification. [1] This classification system is presented also in Figure 4. In Salter-Harris classification system there are six different classes of growth plate fractures:

- Type I: In this type of fracture the epiphysis is completely separated from the end of the bone, or the metaphysis. However, the vital portions of the growth plate remain attached to the epiphysis. Usually, all type I injuries require only a cast for immobilization. [16] Prognosis is usually excellent because of the preservation of the reserve and proliferative zones. [1] Although, if there is a damage to the blood supply, complete or partial growth arrest may occur. [16]
- Type II: This is the most common type of growth plate fracture. [16] Transphyseal fracture that exits through the metaphysic, and the periosteal hinge is intact on the side with metaphyseal fragment. Metaphyseal fragment is known as the Thurston-Holland fragment. [1] Type II fractures are typically reduced and immobilized for normal growth to continue. [16] Prognosis of this type is excellent, although complete or partial growth arrest may also occur in displaced fractures. [1]
- Type III: This fracture occurs only rarely and common fracture point is at the lower end of the tibia. [16] In this types of injuries, there is a transphyseal fracture that separates part of the epiphysis and growth plate from the metaphysis, causing intra-acrticular disruption as well as disrupting the reserve and proliferative zones. Anatomic reduction and fixation without violating the physis are essential. [1] Prognosis for growth is good if the blood supply to the separated portion of the epiphysis is still intact, if the fracture is not displaced, and if a bridge of new bone has not formed at the site of the fracture. [16] Otherwise prognosis is guarded, since blood supply damage and consequently the partial growth arrest and resultant angular deformity. [1]
- Type IV: Type IV injuries occur most commonly at the distal head of the humerus. [16] Type IV fractures traverse the epiphysis and the physis, exiting the metaphysis and disrupting all four zones of

the physis. [1]Surgery is crucial to restore the joint surface to normal and to perfectly align the growth plate. If the perfect alignment can not be achieved, the prognosis for growth is poor and partial growth arrest and resultant angular deformity are likely. [16]

- Type V: This uncommon injury occurs when the end of the bone is crushed and the growth plate is compressed. Most common injury points are at knee or ankle. Prognosis is poor, since this type of injury may be able to cause irreversible and progressive damage to the growth cartilage [9, 11, 12] and to result in premature physeal closure. [16]
- Type VI: Usually, this kind of injury is the result of an open injury. In type VI injury, perichondral ring is damaged at the periphery of the physis. Prognosis is guarded, because peripheral physeal bridges are relatively common. [1]

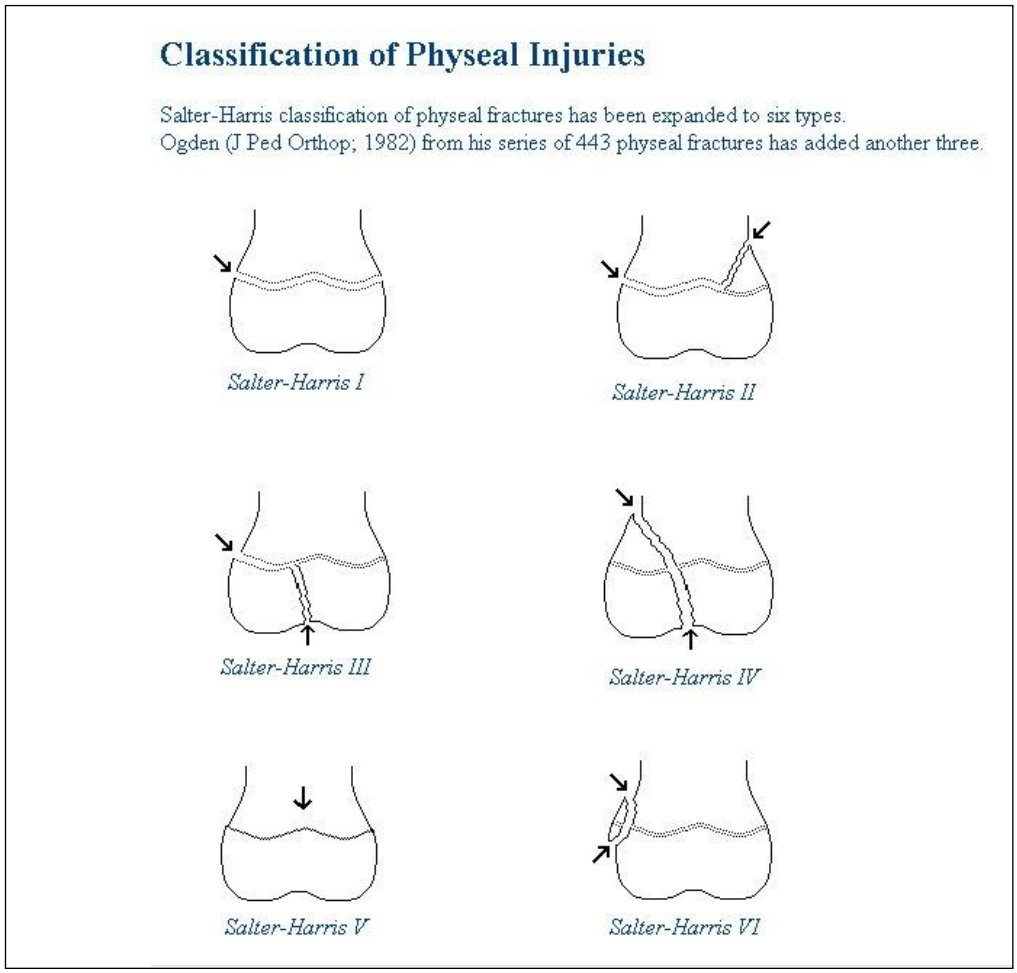

Figure 4: Physeal fractures; Salter-Harris classification **[17]**

Other used classification systems, Poland's and Ogden's classification systems are shown in Figure 5. All three systems are similar, but from left to right are increasingly complex. Salter-Harris classification is a refinement of Poland's system, and Ogden's classification, which is all-inclusive, adds more subclasses to simpler systems

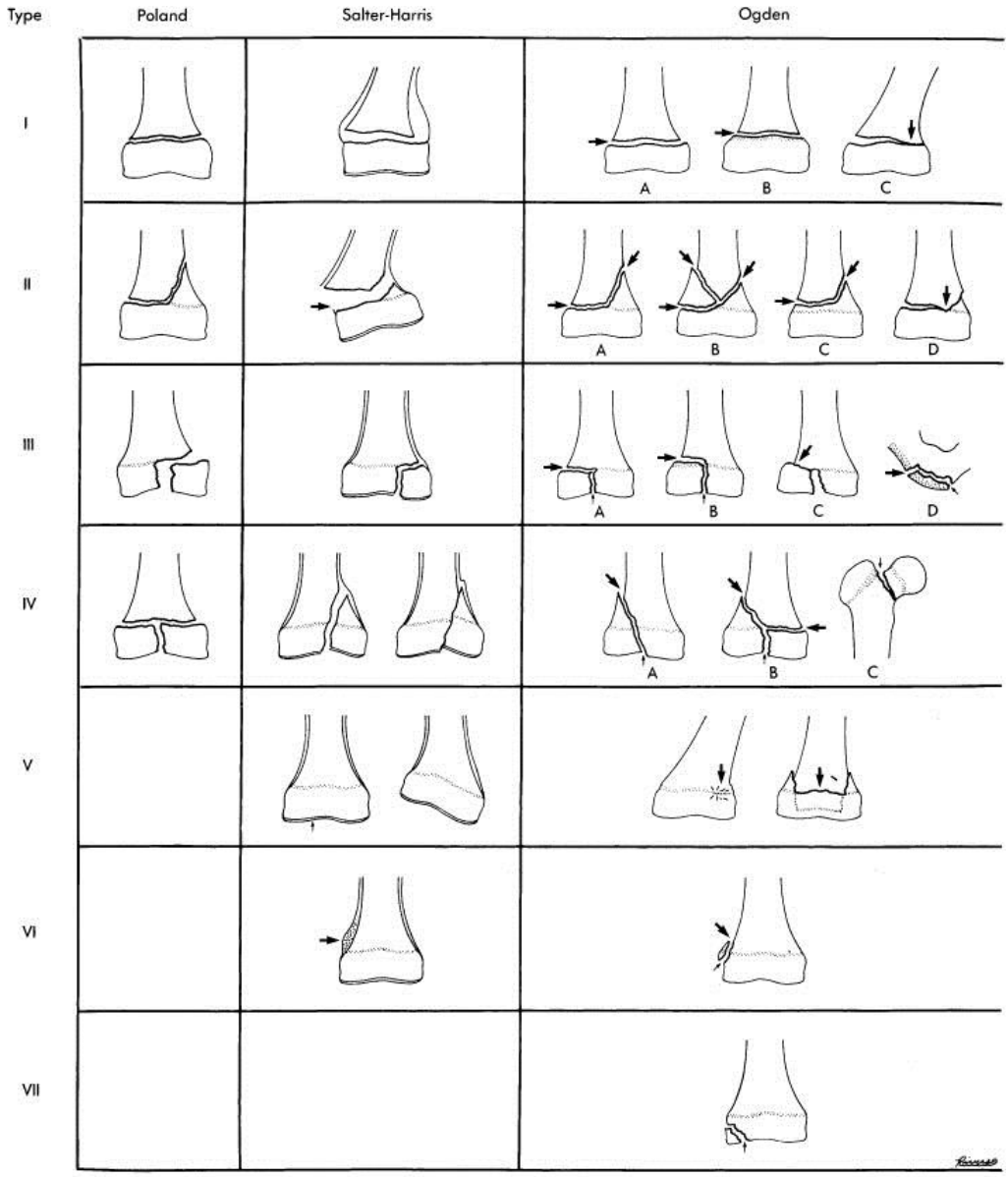

Figure 5: Classification of physeal injuries by Poland, Salter and Harris, and Ogden. **[18]**

3.3. General information about on physeal injuries

Several other mechanisms besides fractures may lead to physeal injuries and to partial/complete growth arrest. These mechanisms are less likely, although plausible. For example, infections, iatrogenic or thermal injuries, neoplasms, metaboloic abnormalities and repetive stress injuries pertain to this group. These may cause premature closure of the physis or partial/complete growth arrest.

Growth plate heals with cartilage repair, unlike other parts of the long bones, which heal with callus formation. Growth plate fracture starts its healing process by filling the fracture gap with fibrin as in typical inflammatory phase. This continues with reparative phase, however in physeal fracture healing process, there is no remodelling phase like in normal bone fracture healing processes. [3]

4. Fixation of physeal fractures

The fixation of the physeal fractures should be considered throughout since fixation method may lead to growth disorders due to destruction of epiphyseal circulation which inhibits the physeal growth, or by formation of bone bridge to form across growth plate (also known as physeal bar) [15] large majority of these fractures heal without any impairment of growth mechanism but some lead to clinically important shortening & angulation [15] Drill holes may also cause iatrogenically created pathological fractures in the future. [18] Consequently, crossing the physis with any form of fixation should be avoided as long as possible. In some cases this is inevitable, however, in some fractures, fixation devices can be placed parallel in the epiphysis or crossed the metaphysis, instead of disturbing the physis. [18] In Figure 6 and Figure 7, general fixation methods for the Salter-Harris Type IV -fracture are presented.

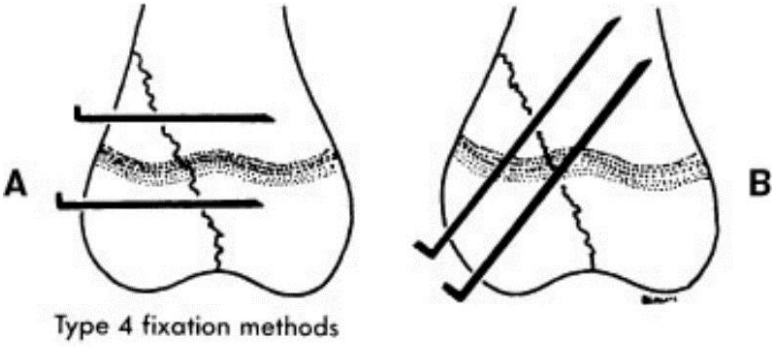

Figure 6: A, Correct placement of parallel smooth pins across epiphysis and metaphysis. B, Smooth pins should cross physis only if necessary to hold reduction. **[19]**

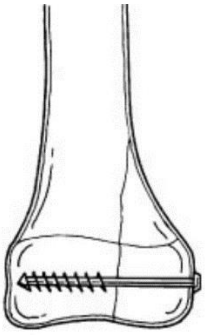

Figure 7: Fixation of physeal fracture. If threaded pins or cancellous screws are used, they should cross epiphysis or metaphysis and not physis. **[20]**

As a fixation device, smooth pins with a small diameter, that can be removed readily are preferred. [18] According to Speed and Macey small wire nails that are crossing the growth plate and are removed after several weeks, caused no significant growth disturbance [21]. Siffert studied the effect of the transepiphyseal wires placed perpendicular to the growth plate with rabbits and reported that wires caused no interference with the longitudinal growth, even though bone bridge could be seen after a transphyseal drill injury [22] Threaded pins or screws placed across the growth cartilage may cause growth arrest if the threads were of sufficient gauge to fix mechanically the epiphysis to the metaphysis until the growth plate was closed; smooth metallic pins or nails of small gauge traversing the growth plate at a perpendicular angle might cause less growth retardation than a cancellous- bone bridge of equal size. [23] However, in many cases growth continued in spite of bone bridge formation indicating that the bone bridge must have fractures owing to the pressure of the growth [2] Pressure of growth is the mechanical force caused by the growth of the growth cartilage. Sijbrandij has been estimated indirectly the pressure of growth by inhibiting the growth of proximal tibial physis of rabbits with 3 kg weight to 15 g per square mm in the cross-sectional area of the growth plate. [24] According to Strobino et al. the pressure of the growth is 45 pounds per square inch (0.3 MPa) in the proximal tibial physis of a calf. [25]

Even though pediatric patients have incredible ability to remodel, the growth plate is a delicate part which is very prone to deformities. However, the better the deformity is tolerated when the fracture is closer to the physis, rotational deformities doesn't spontaneously be corrected or remodeled to an acceptable extent even in the young child and consequently should be avoided [1] and adequate reduction provided. [18] Displaced intra-articular fracture (Salter-Harris types III and IV), fractures with vascular injury or associated compartment syndrome and unstable fractures that require abnormal positioning to maintain closed reduction are the main indications for open reduction [1].

5. Fixation of physeal fractures by bioabsorbable devices

The effect of Bioretec Ltd. SR-PLGA ActivaPin™ or ActivaScrew™ upon the healing of the growth plate has not been tested in clinical studies. However, successful use of the other bioabsorbable implants in physeal fractures has been reported. Mäkelä et al. showed that a 2 mm empty drill hole across the femoral physis in rabbits doesn't cause a permanent growth disturbance, whereas a 3.2 mm empty drill hole did. [26]. Their conclusion was that destruction of 7% or more of the cross-sectional area of the growth plate could result in tethering and the resultant shortening of the femur. [27] SR-PGA pins, PLLA-PGA- copolymer pins, and PDS pins have demonstated no growth disturbance when used for transepiphyseal fracture fixation in animal studies as long as the pins size remains 3 % or less of the growth plate [28, 29, 30].

Cady et al. studied the effect of absorbable polydioxanone (1.3 mm PDS) bone pins on physeal response of growing rabbits [26] In their study there was no evidence of inflammation, foreign body reaction, or distortion of the growth plate during the entire growth period. This suggested bioabsorbable pins do not cause any appreciable inflammatory response or adverse effect on physeal function during active longitudinal growth of bone [31]

Fixation of physeal fractures with bioabsorbable devices are presented successfully at least in the following indication: fracture of the lateral humeral condyle, fractures of the medial condyle and medial epicondyle of the humerus, fractures of medial malleolar [32, 33]. Especially polyglycolide was used as an implant material. [34, 35, 36]

Since August 1987, fractures in children have been treated surgically with bioabsorbable implants [29] after intensive experimental studies on young rabbits [2]. Hope et al. reported better results with the use of SR-PGA pins than with Kirschner wires in the fixation of elbow fractures in children. [36] 1,5 mm SR-PGA pins were used in 19 physeal fractures of the distal humerus in children succesfully without displacement or growth disturbance afterwards [37] Böstman et al. described the use of biodegradable fixation (polyglycolic acid) across the physis for fixation of distal humeral physeal fractures. [18] They obtained excellent temporary fixation without secondary displacement or signs of growth disturbance. They had only one exception where the polyglycolide pins broke, why severe displacement of one supracondylar fracture were reported. However, because of their good results, and the fact that a second procedure for hardware removal is not required, they recommended biodegradable fixation for physeal fractures. [35] Svensson et al. (1994) used 1.5-2.0 mm PGA pins in the fixation of 50 cases of transphyseal and osteochondral fractures which were followed up for at least one year and showed healing in all but two cases with non-union. [34]

Between 1986 and 1994, 57 consecutive patients with a distal humeral fracture were treated operatively using absorbable implants; 15 of them were treated by combining absorbable pins or screws with metallic implants. The clinical outcome was reviewed in 44 patients with an average follow-up time of 4.6 years. The functional results by Broberg and Morrey were excellent or good in 36 (81 %), fair in three (6.8 %), and poor in five (11,2 %) patients. The elderly had more severely unstable fractures and more unfavourable results than the younger patients. The results were favourable in the non-comminuted epicondylar and condylar fractures of the distal humerus as well as in the humeral capitellum fractures. The results were unsatisfactory in the comminuted intra-articular distal humeral fractures [38] From September 1987 to September 1992 five medial malleolar fractures were fixed with bioabsorbable devices without any complications. [39]

6. Upper extremities

Eighty percent of humeral growth occurs at the proximal physis, giving this region great remodeling potential. This and other percentages are seen in Figure 8. [18]

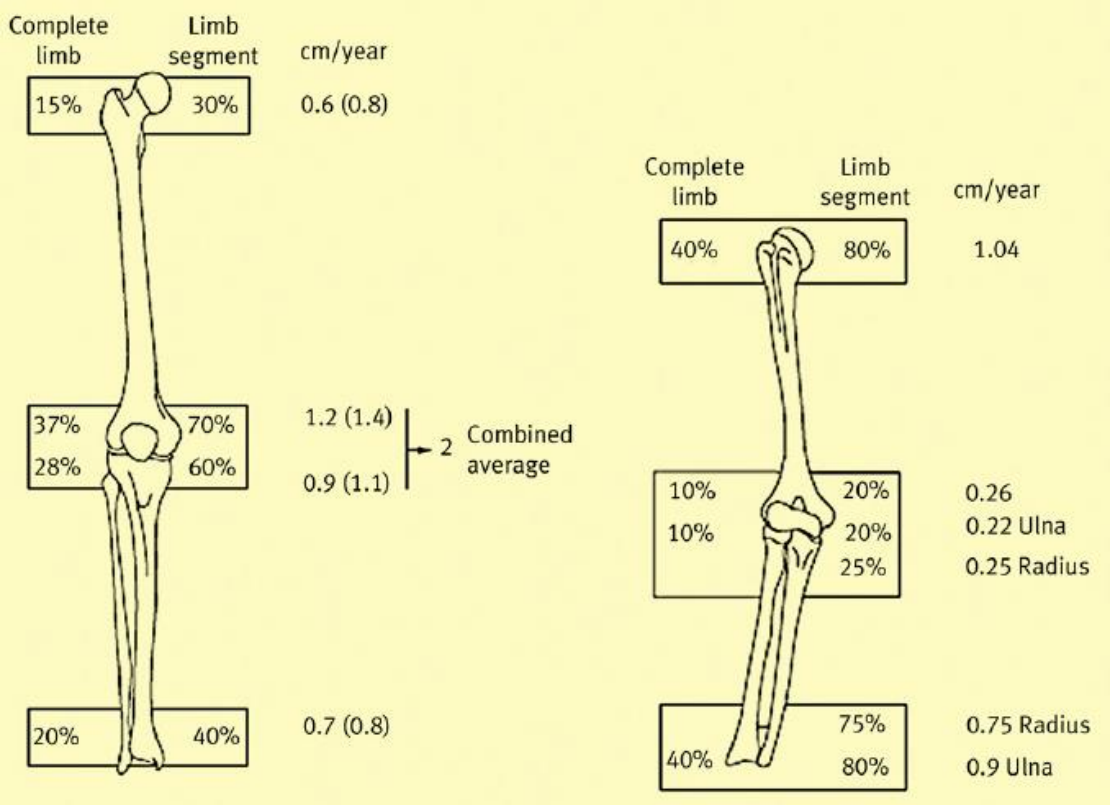

Figure 8: Proportion of growth for each physis. **[40]**

6.1. Physeal fracture of the lateral humeral condyle

This type of fracture accounts for one fifth of the fractures of the elbow in children [32]. Fractures of the distal humerus in children are most often supracondylar or involve a single condyle. [18] The fractured fragment may be secured with two crossed, smooth pins or Kirshner wires that diverge in the metaphysic [1] The passage of smooth pins through the physis does not typically result in growth disturbance [1] Different authors have suggested various forms of fixation, including (1) suture fixation, which is inadequate; (2) smooth pin fixation, preferably with two pins, either through the epiphysis or through the metaphyseal spike; and (3) screw fixation, preferably through the metaphyseal area. [18] However, Conner and Smith used a Glasgow screw through the physis and through the epiphysis and did not notice any growth disturbance. [18] Speed noted that screws could be put through the physis, however, he had little difficulty with cubitus valgus resulting from premature closure in his patients. [18] In Figure 9, different methods are shown for lateral condylar fixation.

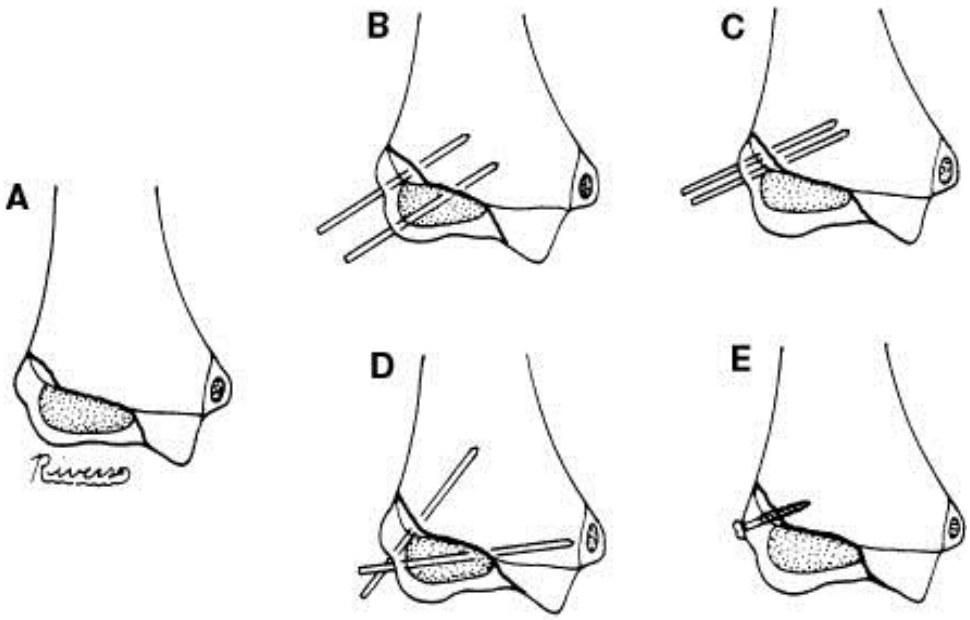

Figure 9: Different methods of fixation of lateral condylar fractures. A, Fracture pattern. B, Parallel pins. C, Parallel pins through metaphysis only. D, Cross pin fixation. E, Cancellous screw fixation. **[41]**

In Figure 10, suggested fixation method for the Salter-Harris Type III or IV lateral humeral condyle fracture.

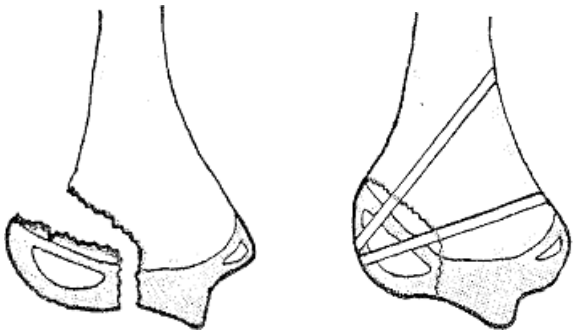

Figure 10: The indication for internal fixation is Salter-Harris Type III or IV fracture of the lateral humeral condyle with dislocation of the fracture exceeding 2 mm. **[32]**

According to Rokkanen et al. the goal of the operative treatment is naturally to restore the anatomy of the growth plate using hairline reduction followed by fixation with small-diameter biodegradable rods (1,5 or 2,0 x 30-60 mm). A lateral incision is preferred over the lateral condyle. Postoperatively a padded plaster splint is used for four weeks with the elbow joint flexed 90 degrees and the forearm in mid-position. [32]

6.2. Physeal fracture of the medial condyle and medial epicondyle of the humerus

Fractures of the medial epicondyle account for one tenth of fractures of the elbow in children. Whereas medial condyle fractures are more common in adults. The fixation of fractures of the medial condyle and medial epicondyle of the humerus can be safely done with bioabsorbable rods. [32] Two smooth Kirschner wires or pins are suggested to the condylar fragment and into the humerus in a proximal and lateral direction. [18] In Figure 11 can be seen the suggested method to treat physeal fracture of the medial condyle and medial epicondyle of the humerus.

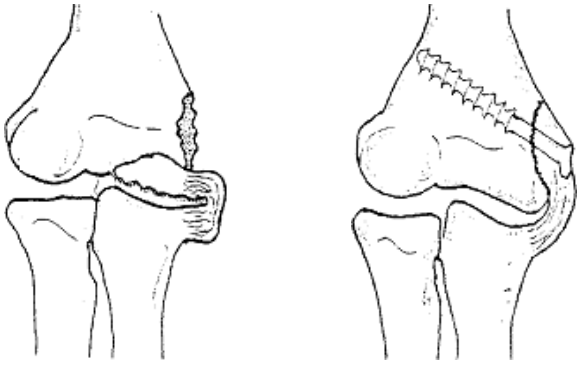

Figure 11: The indication for internal fixation is dislocated (> 5 mm) fracture of the medial condyle or the medial epicondyle of the humerus. **[32]**

The operation technique according to Rokkanen et al. is presented following: SR-PGA rods 1,5/2,0 x 30-60 mm are suggested to be drilled crosswise through the epicondyle, the humeral metaphysis, and, finally, through the cortex on the side opposite to the insertion. A medial incision is made, centered on the medial epicondyle. Sometimes screws are needed to attach the bigger fragments, then SR-PGA screws 3,5 x 30-40 mm are suggested. Postoperatively a padded plaster splint is used for four weeks with the elbow joint flexed 90 degrees and the forearm in mid-position. [32]

6.3. Distal radius fractures

Fractures of the distal third of the forearm are extremely common. [18] In distal radius fractures smooth pins can be used across the physis through the radial styloid. A metal plate shouldn't be used in this area because of the possibility of damaging the physis (compression plate fixation techniques can be used in older children as in adults, but the physis must be avoided). [18]

When dealing with Salter-Harrisn type III fracture in distal radius, open reduction and internal fixation with smooth pins or screw parallel to the physis is recommended if the fracture is inadequately reduced. Whereas with Salter-Harrisn type IV fracture, open reduction and internal fixation is indicated if the fracture is displaced. In type IV fractures growth disturbance is likely. [1]

7. Lower extremities

When the fixation method of the physeal fracture in the lower extremities is considered, it is good to take in concern how much growth to the lower extremities that physis contributes. For example evev two-thirds of longitudinal growth of the lower extremity is provided by the distal femoral physis (9mm/year) and proximal tibial physis (6 mm/year) [1]. Whereas, the proximal femur contributes only 15% to the entire lower extremity [6]. Fixation method should be selected so that there wouldn't be (nearly) any growth disturbances and hence leg discrepancies.

7.1. Hip fracture (Proximal femur)

As mentioned above proximal femoral physis contributes 15% to the entire lower extremity and 30% to the growth of the femur. It is also said that it normally closes earlier than most of the other lower extremity physes [18] Open reduction and internal fixation (pinning) may be necessary in proximal femur fraction if the fracture is irreducible by closed method. [1] In some cases, crossing the physis may be necessary to gain union, however, especially in younger children, smooth pins should be used in these situations. [18] However, penetrating the physis should be avoided, especially in children younger than 9 years, since the risks of

premature physeal closure is high (incidence is ≤60%) and increased incidence with pins penetrating the physis. It may result in femoral shortening, coxa vara and short femoral neck. [1]

7.2. Distal femur

Distal femoral fractures account 6-9 % of physeal fractures. These injuries have a high incidence of physeal arrest (27.3-90 %). [10] Distal femur is in a major part when the growth of the lower extremities is considered. Distal femoral epiphysis is the largest and fastest growing physis in the body [1] Most common injury in the distal femoral physis is Salter-Harris II type fracture [1]. To minimize residual deformity and growth disturbance crossing the physis should be avoided if possible. However, if the physis must be crossed, smooth pins as perpendicular as possible are preferred. [1] Canale and Beaty suggest crossed 2.4 mm unthreaded Steinmann pins through the medial and lateral condyles and into the metaphysis (see Figure 12). If a large metaphyseal spike (Salter-Harris II) is present after closed reduction, horizontal percutaneous pins or screws are suggested. It is adviced that if the pins are inserted as described and removed at 4 to 6 weeks after insertion, they are unlikely to cause any growth disturbance. [18]

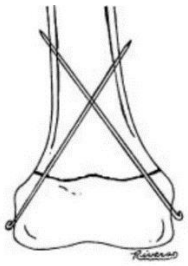

Figure 12: Cross wire fixation with aid of image intensifier. Smooth pins should be used and should penetrate opposite cortex. **[20]**

If a type II or IV fracture has a large metaphyseal spike, then rather than using smooth crossed pins, two 2.4 mm threaded pins or a cancellous screw through the metaphysis of the spike into the proximal metaphyseal portion of the fracture are preferred (in Figure 13). This should provide good stability and avoids crossing the physis. [18]

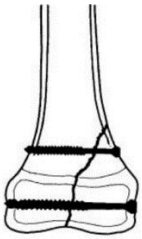

Figure 13: Salter-Harris type IV fracture metaphyseal spike is secured transversely with cancellous screw. **[20]**

7.3. Physeal fractures of proximal tibia

Proximal tibial physis provides 6 mm growth/year and therefore is relatively important factor to the length of the legs [1]. The physis of the proximal tibia is well protected by osseous and soft tissue structures, which may account for the low incidence of injuries to this structure. However, tibial tubercle physis, which is continuous with the tibial plateau, is the most vulnerable between the ages of 13 and 16 years. [1]

A vertical midline approach is used for fixation of the proximal tibial physis fracture. Fracture can be stabilized by using smooth pin (> 3 years from skeletal maturity), screws, threaded Steinmann pins, or a tension band. [1] Displaced non-stable Salter Type I or II fractures may be treated with percutaneous smooth pins across the physis (Type I) or parallel to the physis (metaphysic) in Type II. These are presented in Figure 12 and Figure 13. Open reduction and internal fixation are usually indicated for displaced Salter-Harris Types III and IV to restore articular congruity. This may be achieved with pin or screw fixation parallel to the physis. [1]

7.4. Physeal fractures of distal tibia and fibula

Ankle injuries account for 25-38 % of all physeal injuries and distal tibia and distal fibula are the most common fractures in children and adolescents. [42] Tibial physeal fractures are most common from 8 to 15 years of age, and fibular physeal injuries are most common from 8 to 14 years of age [1] Lateral portion of the distal tibial physis remains open over an 18-month period the while the medial part has closed at the age of 15 to 17 [1] The physis is the biomechanically weak link when a twisting injury is applied to the foot and ankle, and most of the injuries to the foot and ankle have some component of physeal injury associated with them. [42]

Kling et al. reported that in some types III and IV fractures fixed with smooth pins that crossed the physis, the physis closed prematurely by forming a bony bridge in the area where the pins crossed the plate. [18] Complete or partial arrests can lead to limb length discrepancy as well as angular deformities. Intra-articular fractures exhibit the highest rate of growth disturbance (i.e. physeal bar formation) [1] Consequently it is sugested that Salter-Harris type III or IV fractures should be fixed by horizontal pins or cancellous bone screws not involving physis (Figure 14). [18]

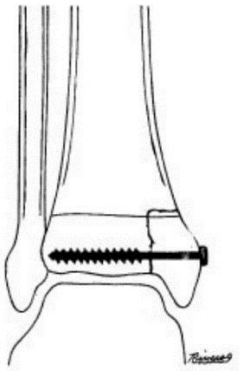

Figure 14: Salter-Harris type III or IV fracture should be fixed by horizontal pins or cancellous bone screws not involving physis. **[20]**

7.4.1. Lateral malleolar (distal fibula) fracture

In this case, it is suggested to perform open reduction (with interposed periosteum if needed), with fixation using an intramedullary Kischner wire perpendicular to the physis for Salter-Harris III and IV fractures. [1]

7.4.2. Medial malleolar (distal tibia) fracture

With medial malleolar fracture it is suggested to perform an open reduction, with placement of a transmetaphyseal compression screw or Kischner wire parallel and proximal to the physis for Salter-Harris I and II fractures [1] For Salter-Harris III and IV fractures, it is suggested to perform open reduction and internal fixation with an anteromedial approach with cancellous screw(s) placed parallel below and/or above the physis [1] (Figure 15).

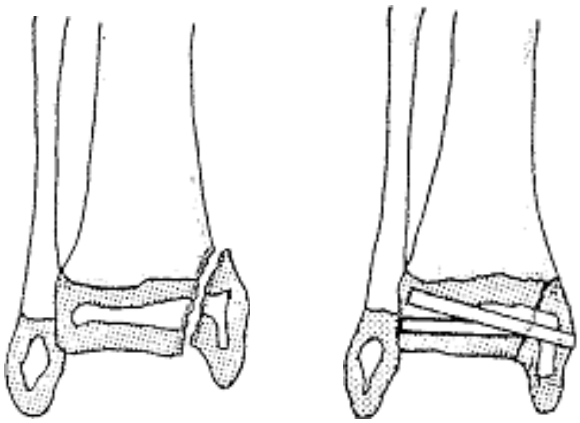

Figure 15: The indication for internal fixation is the Salter-Harris Type IV fracture of the medial malleolus with dislocation of the fracture exceeding 2 mm. **[32]**

Fixation of medial malleolar fractures with small-diameter bioabsorbable rods ensures undisturbed healing of a physeal fracture and also minimizes the risk of growth disturbances if the fixation rods have to be driven through the growth plate. [32] Rokkanen et al. studied SR-PGA rods 1,5 x 40-50 mm for the medial malleolar fracture. They made an open reduction with medial incision. Postoperatively a padded and split plaster (closed in 3-5 days) cast with the ankle joint of 90 degrees in flexion is used for six weeks. [32]

7.4.3. Tillaux fracture

Triplane and tillaux fracture patterns in adolescents occur as a result of the ossification pattern of the distal tibia. Ossification starts centrally and then progresses anteromedial, then posteromedial, and ends laterally. This circular pattern of ossification is responsible for these fractures with external rotation injuries in adolescents. Tillaux fractures are Salter Harris III avulsion fractures of anterolateral tibia epiphysis with external rotation force leading to anterior tibiofibula ligament avulsion. This tends to occur in adolescents during a window while the lateral physis is the last remaining part of the distal tibia that remains open. [42] Open reduction and internal fixation may be achieved via an anterolateral approach with two smooth pins parallel or a small cancellous screw [1] (4.0 mm cannulated cancellous screw [42]) transversely across the fracture but not penetrating the physis. [18] However, care is taken to protect the superficial peroneal nerve and the distal tibial articular surface while dissecting down to the fracture site. [42] The screw can be placed also across the physis if necessary (Figure 16). [42]

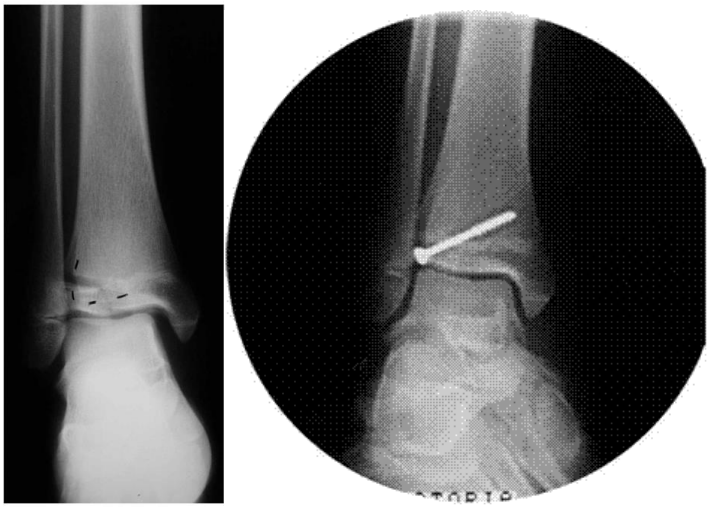

Figure 16: Tillaux fracture and its fixation. **[42]**

7.4.4. Triplane fracture

The reduction is similar to Tillaux fractures, but multiple screw placement is required to hold the reduction with the anteroposterior plane in the metaphysis and in the epiphysis. Triplane fractures also carry the risk of physeal bar formation, leading to growth irregularity. [42]

8. Conclusions

Pediatric physeal fractures have traditionally described by the Salter-Harris classification in which displaced fractures of types III and IV often require open reduction and internal fixation in order to integrate intra-articular disruptions. According to general instruction, crossing the physis with any form of fixation should be avoided, if possible, in order to prevent growth disorders, such as complete growth arrest and progressive angular or rotational deformities due to destruction of epiphyseal circulation (inhibits physeal growth), or by formation of bone bridge (a physeal bar) across growth plate.

However, if the fixation of physeal fractures by crossing through the growth plate is demanded, fixation with small bioabsorbable pins can be safely done without significant growth disturbance, as the pins size remains 3 % or less of the total cross-sectional area of the growth plate. The advantage of the bioabsorbable device fixation in physeal fractures of children is that a second procedure for hardware removal is not required. The effect of ActivaPin™ or ActivaScrew™ upon the healing of the growth plate has not been tested in clinical studies.

General instructions: The goal of the operative treatment is to restore the anatomy of the growth plate using hairline reduction followed by fixation with small-diameter biodegradable rods. In the physeal fracture the reposition of the cartilaginous fragments as anatomically as possible is important; otherwise, the resulting offset will cause a bony bridge and joint incongruity. Try not to cross the physis, but if necessary, place transpepiphyseal pins perpendicular to the growth plate - in this way the devices do not cause significant interference with the longitudinal growth. Use pins rather than threaded k-wires or screws to ensure undisturbed healing of a physeal fracture and to minimize the risk of growth disturbances. Avoid unnecessary drill holes that later may become iatrogenically created pathological fractures. Use appropriate additional immobilization (e.g. suitable cast, brace) during bone healing. Pins or nails of small diameter traversing the growth plate at a perpendicular angle cause less growth retardation than, e.g. a cancellous bone bridge of equal size. If threaded k-wires or screws are placed across the growth plate and they mechanically fix the epiphysis to the metaphysis, they may cause growth arrest. In the cases of physeal fractures the growth disorders are common in spite of used fixation method, therefore the parents have to be warned complications such as bony bridge formation, angular deformity, and avascular necrosis.

9. References

[1] K. Koval and K. Zuckerman, Handbook of Fractures, 2006.

[2] E. Mäkelä, "Fixation properties and biodegradation of absorbable implants in growing bone, an experimental and clinical study," Helsinki, 1989.

[3] E. Dodwell and S. Kelley, "Physeal fractures: basic science, assessment and acute management," *Orthopaedics and trauma,* vol. 25, no. 5, pp. 377-391, 2011.

[4] "Epiphyseal Plate (Growth Plate)," Pubmed health, [Online]. Available: https://www.ncbi.nlm.nih.gov/pubmedhealth/PMHT0027349/. [Accessed 3 July 2017].

[5] H. Peterson, "Chapter 2," in *Epiphyseal growth plate fractures*, Springer science+Business media, 2007, p. 8.

[6] A. Arkader and D. Skaggs, "Physeal Injuries," in *Green's Skeletal Trauma in Children E-Book*, Elsevier Health Sciences, 2014, pp. 16-35.

[7] G. Dale and W. Harris, "Prognosis of epiphysial separation: an experimental study," *Journal of Bone & Joint surgery. British volume,* Vols. 40-B, no. 1, pp. 116-122, 1958.

[8] K. Pichler, G. Musumeci, I. Vielgut, E. Martinelli, P. Sadoghi, C. Loreto and A. Weinberg, "Towards better understanding of bone bridge formation in the growth plate - an immunohistochemical approach," *Connective tissue research,* vol. 54, no. 6, pp. 408-415, 2013.

[9] C. Basener, C. Mehlman and T. DiPasquale, "Growth disturbance after distal femoral growth plate fractures in children: a meta-analysis.," *Journal of Orthopaedic Trauma,* vol. 23, pp. 663-667., 2009.

[10] B. Garret, E. Hoffman and H. Carrara, "The effect of percutaneous pin fixation in the treatment of distal femoral physeal fractures," *The journal of Bone & Joint Surgery,* Vols. 93-B, pp. 689-694, 2011.

[11] D. Lennox, R. Goldner and M. Sussman, "Cartilage as an interposition material to prevent transphyseal bone bridge formation: an experimentalmodel.," *Journal of Pediatric Orthopaedics,* vol. 3, p. 207–210, 1983.

[12] M. Tobita, M. Ochi, Y. Uchio, R. Mori, J. Iwasa, K. Katsube and T. Motomura, "Treatment of growth plate injury with autogenous chondrocytes: a study in rabbits.," *Acta orthopaedica Scandinavica,* vol. 73, p. 352–358, 2002.

[13] C. Hasler and B. Foster, "Secondary tethers after physeal bar resection: a common source of failure?," *Clinical Orthopaedics and Related Research,* vol. 405, p. 242–249, 2002.

[14] A. Clark, J. Hilt, T. Milbrandt and D. Puleo, "Treating Proximal Tibial Growth Plate Injuries Using Poly(Lactic-co-Glycolic Acid) Scaffolds," *BioResearch Open Access,* vol. 4, no. 1, p. 65–74, 2015.

[15] C. Wheeless, "Salter Harris Classification of growth plate fractures," Wheeless' textbook of orthopaedics, 31 May 2012. [Online]. Available: http://www.wheelessonline.com/ortho/salter_harris_classification_of_growth_plate_fractures. [Accessed 3 July 2017].

[16] National Arthritis and Musculoskeletal and Skin Diseases, "Growth Plate Injuries," Center for Orthopaedics & Sports Medicine, [Online]. Available: http://arthroscopy.com/injuries-ailments/growth-plate-injuries/. [Accessed 3 July 2017].

[17] "Physeal Fractures," Orthoteers, [Online]. Available: http://www.orthoteers.org/(S(l2hdejjjrnpmfl45u5ssfcfx))/mainpage.aspx?section=27&article=311.

[18] S. Canale and J. Beaty, "Fractures and dislocation in children," in *Cambell's Operative Orthopaedics, Volume 2*, Elsevier Health Sciences , 1998, pp. 1393-1523.

[19] J. Ogden, in *Skeletal Injury in the Child*, Philadelphia, Lea & Febiger, 1982.

[20] B. Weber, C. Brunner and F. Freuler, in *Treatment of fractures in children and adolescents*, New York, Springer-Verlag, 1980.

[21] J. Speed and H. Macey, "Fractures of the humeral condyles in children.," *Journal of Bone and Joint Surgery,* vol. 15, pp. 903-919, 1933.

[22] R. Siffert, "The effect of staples and longitudinal wires on epiphyseal growth. An experimental study.," *The Journal of Bone and Joint Surgery. American Volume,* vol. 38, p. 1077, 1956.

[23] C. Cambell, A. Grisolia and G. Zanconato, "The effects produced in the cartilaginous epiphyseal plateof immature dogs by experimental surgical traumata," *The Journal of bone and joint surgery. American volume,* vol. 41, p. The Journal of bone and joint surgery. American volume, 1959.

[24] S. Sijbrandij, "Inhibition of tibia growth by means of compression of its proximal epiphyseal disc in the rabbit. . 55, 278-285.," *Acta Anatomica Journal,* vol. 55, pp. 278-285, 1963.

[25] L. Strobino, P. Colonna, R. Brodey and T. Leinbach, "The Effect of Compression on the Growth of Epiphyseal Bone," *Surgery, Gynecology & Obstetrics,* vol. 103, no. 1, pp. 85-93, 1956.

[26] R. Cady, J. Siegel, G. Mathien, J. Spadaro and S. Chase, "Physeal response to absorbable polydioxanone bone pins in growing rabbits," *Bioned. Mater. Res. (Appl. Biomater.),* vol. 48, no. 3, pp. 211-215, 199.

[27] E. Mäkelä, S. Vainioinpää, K. Vihtonen, M. Mero and P. Rokkanen, "The effect of trauma on the lower femoral epiphyseal plate. An experimental study in rabbits.," *Journal of the Bone and Joint Surgery,* vol. 70B, p. 187, 1988.

[28] D. Rovinsky, R. Durkin and N. Otsuka, "The use of bioabsorbables in the treatment of childen's fractures," *Techniques in Orthopaedics,* vol. 13, no. 2, pp. 130-138, 1998.

[29] O. Böstman, E. Mäkelä, P. Törmälä and P. Rokkanen, "Transphyseal fracture fixation using biodegradable pins.," *The Journal of Bone and Joint Surgery. British volume,* vol. 71, pp. 706-707, 1989.

[30] N. Otsuka, J. Mah, F. Orr and R. Martin, "Biodegradation of polydioxanone in bone tissue: effect on the epiphyseal plate in immature rabbits.," *Journal of Pediatric Orthopaedics,* vol. 12, pp. 177-180, 1992.

[31] R. Cady, J. Siegel, G. Mathien, J. Spadaro and S. Chase, "Physeal Response to Absorbable Polydioxanone Bone Pins in Growing Rabbits," *Journal of Biomedical Materials Research ,* vol. 48, no. 3, pp. 211-215, 1999.

[32] P. Rokkanen, O. Böstman, E. Hirvensalo, E. Mäkelä, E. Partio, H. Pätiälä, S. Vainionpää, K. Vihtonen and P. Törmälä, "Bioabsorbable fixation in traumatology and orthopedics (BFTO),," University of Helsinki, 1997.

[33] P. Rokkanen, O. Böstman, E. Hirvensalo and e. al, "Biofix: Absorbable fixation in orthopedic surgery (AFOS): Surgical technique," University of Helsinki, 1996.

[34] P. Svensson, P. Janarv and G. Hirsch, "Internal fixation with biodegradable rods in pediatric fractures: one-year follow-up of fifty patients.," *Journal of Pediatric Orthopaedics,* vol. 14, pp. 220-224, 1994.

[35] O. Böstman, E. Mäkelä, J. Södergård, E. Hirvensalo, P. Törmälä and P. Rokkanen, "Absorbable polyglycolide pins in internal fixation of fractures in children," *Journal of Pediatric Orthopaedics,* vol. 13, p. 13, 1993.

[36] P. Hope, D. Williamson, C. Coates and W. Cole, "Biodegradable pin fixation of elbow fractures in children. A randomised trial.," *The Journal of Bone and Joint Surgery,* Vols. 73-B, pp. 965-968, 1991.

[37] E. Mäkelä, O. Böstman, M. Kekomäki, J. Södergård, J. Vainio, P. Törmälä and P. Rokkanen, "Biodegradable fixation of distal humeral physeal fractures.," *Clinical Orthopaedics and Related Research,* vol. 283, pp. 237-243, 1992.

[38] K. Pelto-Vasenius, E. Hirvensalo and P. Rokkanen, "Absorbable implants in the treatment of distal humeral fractures in adolescents and adults.," *Acta Orthopaedica Belgica,* vol. 62 (suppl 1), pp. 93-102, 1996.

[39] E. Mäkelä, O. Böstman, M. Kekomäki, P. Törmälä and P. Rokkanen, "Absorbable polyglycolide pins in the fixation of fractures in children.," *Biodegradable implants in fracture fixation,* pp. 225-232, 1994.

[40] R. Morissy and S. Weinstein, Lovell and Winter's Pediatric Orthopedics, Lippincott Williams & Wilkins, 2005.

[41] T. Wadsworth, "Injuries of the capitular (lateral humeral condylar) epiphysis.," *Clinical Orthopaedics and Related Research,* vol. 85, no. 127, pp. 127-142, 1972.

[42] H. Chambers and C. Haggerty, "The foot and ankle in children and adolescents," *Operative Techniques in Sports Medicine - Journal,* vol. 14, pp. 173-187, 2006.